



Labial tissue rejuvenation and sexual function improvement using a novel noninvasive focused monopolar radio frequency device

Zeljka Clark

To cite this article: Zeljka Clark (2017): Labial tissue rejuvenation and sexual function improvement using a novel noninvasive focused monopolar radio frequency device, Journal of Cosmetic and Laser Therapy, DOI: [10.1080/14764172.2017.1368565](https://doi.org/10.1080/14764172.2017.1368565)

To link to this article: <http://dx.doi.org/10.1080/14764172.2017.1368565>



Accepted author version posted online: 30 Aug 2017.
Published online: 30 Aug 2017.



Submit your article to this journal [↗](#)



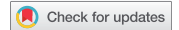Article views: 17



View related articles [↗](#)



View Crossmark data [↗](#)



Labial tissue rejuvenation and sexual function improvement using a novel noninvasive focused monopolar radio frequency device

Zeljka Clark, MD

Rahima Moosa Mother and Child Hospital, O&G, Johannesburg, South Africa

ABSTRACT

Introduction: With aging, the vulvar tissue loses its vitality and elasticity due to collagen fibers fatigue. Such changes and functional characteristics of the external genitalia often cause negative psychological effects resulting in impeded sexual function. The objective of this study is to evaluate the safety and efficacy of a radio frequency (RF) device when used for treating labial laxity and for improvement of female sexual function. **Materials and Methods:** Using a monopolar RF device, 19 women received four once-a-week treatments. Images taken at the baseline and at the 1-month follow-up were evaluated for improvement in vulvar appearance on a scale of 0–3. The female sexual function index (FSFI) scores were calculated and compared between the baseline, the 1-month follow-up visit, and the 12-month follow-up visit. **Results:** Average improvement in the vulvar appearance according to the patients and the physician was 2.00 ± 0.58 and 1.79 ± 0.54 , respectively. Both values represent “moderate change” according to the applied scale. The average FSFI increased by 9.79 ± 4.35 and 7.10 ± 5.17 when comparing the baseline to the 1-month and the 12-month follow-up, respectively. No adverse events were reported. **Discussion:** Efficacy and safety of the investigated device were proven. Longevity of results was proven by the 12-month follow-up.

ARTICLE HISTORY

Received 18 April 2017
Accepted 14 August 2017

KEYWORDS

FSFI; labia rejuvenation;
Radio frequency; sexual
function improvement;
vulvar appearance

Introduction

Collagen is the major structural component of skin that histologically becomes disorganized into collagen fibrils and abnormal elastic material. This is primarily as a result of aging, pregnancy, and childbearing processes. With aging, the vulvar tissue loses its vitality, elasticity is reduced due to fatigue of the collagen fibers, and wrinkles start to appear. These changes are usually accompanied by women's reduced satisfaction with the esthetic appearance of her genitalia.

Regardless of age, education, or socioeconomic status, such anatomical appearance together with physiological and functional characteristics of the external female genitalia often causes negative psychological effects. Embarrassment and anxiety over sexual function leads many women to seek help in ameliorating these conditions and concerns.

One possible treatment solution is represented by surgical remodeling of vulvar tissue (labia minora, labia majora, mons pubis, perineum, and vaginal introitus). Reduction labiaplasty is used for sculpting of elongated or unequal labia minora, mostly in response to labia minora protruding beyond the labia major (1). Perineoplasty is a way to rejuvenate relaxed perineum and can also enhance the sagging labia majora and labia minora. Augmentation labiaplasty can provide esthetic improvement and rejuvenation of labia majora.

The main concerns with surgical procedures and ablative laser resurfacing relate to possible adverse events (infection,

scarring, keloid formation, asymmetrical appearance of the surgically treated tissue) and associated downtime.

Skin rejuvenation options with a low risk of severe adverse events and without (or with very little) downtime include various non-ablative systems: vascular lasers, intense pulse light, infrared lasers and broadband light sources, radio frequency (RF) devices, photodynamic therapy, and fractional lasers. All these devices may be used to achieve restoration of youthful appearance and to improve sexual function and performance.

RF methods were first studied in 1949 for the treatment of skin laxity, resulting in significant improvement in skin tissue appearance (2). However, the application of RF to external female genitalia only began to emerge in the last decade. The RF-induced elevation of tissue temperature leads to a break-up of intermolecular cross links, stabilization of collagen helix structures, and thickening of collagen fibers. The mild inflammatory response of the treated tissue stimulates fibroblasts. As a result, new collagen and elastin fibers are produced as part of the natural healing response (3).

Various RF devices are currently available on the market, with monopolar units penetrating 20–25 mm and bipolar RF reaching depths of approximately 2–8 mm (4). Lordello et al (5) used a bipolar device on women with sagging labial tissue. The protocol consisted of eight 20-minute weekly sessions, reaching a temperature of 39–41°C. All patients reported satisfaction with the treatment outcome regarding

sexual function, arousal, and lubrication. Average female sexual function index (FSFI) score (5) increased from 25.66 ± 5.7 to 27.30 ± 5.5 ($p = 0.379$).

In 2016, a prospective cohort study on 17 women was conducted in Croatia using a monopolar RF device for labial tissue tightening and improvement of labial laxity (5). The investigators reported an average “moderate change” regarding improvement in vulvar appearance. Mean FSFI scores increased from 75% to 87%.

Materials and methods

Study cohort

This is a prospective, randomized, and controlled study which aims to evaluate the safety and efficacy of a monopolar RF treatment when applied to external female genitalia for treating labial laxity and to improve female sexual function.

We enrolled 19 healthy women aged 35–64 (average age 46.7 years) who had reported dissatisfaction with the esthetic appearance of their external genitalia before the commencement of the study. Fourteen of the 19 women had a history of at least one prior delivery. Clinical and demographic characteristics of the subjects are presented in Table 1. The cohort included four postmenopausal subjects, aged 55–64, who had never been exposed to any form of hormone replacement therapy.

Consent to the treatments was obtained prior to commencement, and a detailed medical history of each individual was taken. This included obstetric and gynecological details, and any previous surgeries in the genital area. Each subject was evaluated for contraindications that would disqualify her from receiving RF treatments, including but not limited to pacemakers, defibrillators, facial implants, intradermal fillers, pregnancy, breastfeeding, gynecological or skin lesions in the genital region, or malignancy (6).

The entire study was conducted in compliance with the WMA Declaration of Helsinki’s ethical principles for medical research involving human subjects.

Treatment protocol

The treatment protocol consisted of four weekly sessions, each taking approximately 20 minutes. A monopolar RF device was used (BTL Exilis System, BTL Industries Inc.), with the

starting energy set to 90 points and 100% duty factor. The energy was adjusted based on patient’s feedback.

Thick hydrosoluble gel was applied to skin in the treated area prior to each treatment. The procedure was conducted using slow circular motions in a cranial–caudal direction, covering the mons pubis, labia majora, clitoris, perineum, and vaginal introitus. Light pressure was applied on the hand-piece during the treatment.

All treatments were performed using the same starting setting and the same treatment technique, since monopolar RF application has been found to be safe for all skin types (7).

Outcome measures

Digital photographs of the treated area with patient in a lithotomy position were taken before and after each treatment, 1 month after the last treatment, and 12 months after the last treatment. Lighting conditions were kept constant, and the same digital camera (12MP, HD) was used, placed exactly 30 cm from the genital area.

Both the patients and the physician evaluated the photographs, comparing the baseline images to the images taken 1 month after the final treatment. A 4-point scale system was used to record the improvements in vulvar appearance (0 – no improvement; 1 – mild improvement; 2 – moderate improvement; 3 – excellent improvement).

The FSFI questionnaire was completed by all subjects before the first session, 1 month after the last session, and 12 months after the last session.

All results were checked for statistical significance using the Student’s *t*-test. Values of $p < 0.05$ were deemed statistically significant.

Any adverse events or side effects were recorded.

Results

All 19 women completed the full treatment protocol and the 1-month follow-up visit. Two patients did not undergo the 12-month follow-up visit due to personal circumstances not related to the study.

Sexual function

The following results are based on 15 out of 16 enrolled sexually active women who finished the study (one did not complete the 12-month follow-up visit). When comparing the baseline to the 1-month follow-up visit and the 12-month follow-up visit, the average improvement of sexual function as measured by the FSFI questionnaire was 9.79 ± 4.35 points and 7.10 ± 5.17 points, respectively. Both results show high statistical significance ($p < 0.001$). The average score increased from 22.59 ± 4.00 (baseline) to 32.38 ± 1.68 (1-month follow-up visit) and 29.69 ± 2.97 (12-month follow-up visit). This represents an improvement of FSFI from 63% to 90% and 83%, respectively. For details, see Table 2.

Statistically significant increase in FSFI scores was observed in five out of six FSFI dimensions at both follow-up visits. The improvement in these five dimensions averaged 1.94 points (32pp) and 1.44 points (24pp) 1 month and 12

Table 1. Demographic and clinical profile of the study cohort

Personal history	N	Mean \pm SD or %
Age (years)	19	47 \pm 7.6
BMI (kg/m ²)	19	25.3 \pm 5.2
Sexual activity in the last 6 months	16	84
Sexually inactive	3	16
Oral contraception	2	11
Menopausal	4	21
Birth history		
Caesarean section only	7	37
Vaginal delivery	5	26
Vaginal and caesarean	2	11
No pregnancies	5	26
Race/ethnicity		
Caucasian	12	63
African	5	26
Mixed	2	11

Table 2. Change in the FSFI score 1 month and 12 months after the final treatment

Patient/Pregnancies/Deliveries	Sexual activity	Before	1-Month post Tx	12- Months post Tx	Change 1-Month post Tx	Change 12-Months post Tx
A. No pregnancies	YES	27.5	31.5	31.8	4.0	4.3
B. No pregnancies	YES	23.4	27.9	23.4	4.5	0
C. P2G1 – NVD and ectopic	YES	24	33.6	27	9.6	3
D. P2G2 – NVD	YES	18	31.5	30.3	13.5	12.3
E*. P2G2 0 NVD	YES			Didn't finish the study		
F. P2G2 – 2X C-Section	YES	24.5	30.9	29.2	6.4	4.7
G*. P2G2 – 2X C-Section	NO			Not sexually active		
H. P2G2 – 2X C-Section	YES	22.4	31.4	33.2	9	10.8
I. P1G1 – 1X C-Section	YES	21	34.8	29.9	13.8	8.9
J. No pregnancies	YES	24	33.1	33.9	9.1	9.9
K. No pregnancies	YES	30	33.9	31.8	3.9	1.8
L. P2G2 – 2X C-Section	YES	26	33.7	28.3	7.7	2.3
M. P3G3 – 3X C-Section	YES	13	33	33.3	20	20.3
N. P2G2 – NVD	YES	20	34.5	32.1	14.5	12.1
O. P3G3 – NVD	YES	23	32.2	28.6	9.2	5.6
P*. No pregnancies	NO			Not sexually active. Didn't finish the study		
Q. P3G3 – 2X NVD 1 X C-Section	YES	23.6	32	26.8	8.4	3.2
R. P1G1 – 1X C-Section	YES	18.4	31.7	25.7	13.3	7.3
S*. P4G4 – 3X NVD 1X C-Section	NO			Not sexually active		
Mean ± SD		22.59 ± 4.00	32.38 ± 1.68	29.69 ± 2.97	9.79 ± 4.35	7.10 ± 5.17

*Key: E – 3 deaths to immediate family in the last 12 months
 G – Marriage problems
 P – Subject reported a sexual problem with her husband and did not think she should continue with the survey
 S – Client lost her husband before starting the study

Table 3. Changes in the sexual function

FSFI Dimension	Score range	Pre Tx	1-Month post Tx	P value	12-Months post Tx	P value	Improvement (pre to 1-month Post)	Improvement (pre to 12-months Post)
Desire	(1–5)	3.15 ± 0.90	4.68 ± 0.93	<0.001	4.44 ± 1.05	<0.001	1.53 ± 1.12	1.29 ± 0.95
Arousal	(0–5)	3.43 ± 1.23	5.33 ± 0.43	<0.001	4.86 ± 0.47	<0.005	1.90 ± 1.25	1.43 ± 1.31
Lubrication	(0–5)	3.25 ± 1.23	5.47 ± 0.68	<0.001	4.68 ± 1.64	<0.05	2.21 ± 1.42	1.43 ± 1.84
Orgasm	(0–5)	3.41 ± 0.95	5.49 ± 0.47	<0.001	5.09 ± 0.88	<0.001	2.08 ± 1.08	1.68 ± 1.38
Satisfaction	(0/1–5)	3.55 ± 0.95	5.52 ± 0.70	<0.001	4.96 ± 0.87	<0.05	1.97 ± 1.17	1.41 ± 1.35
Pain	(0–5)	5.80 ± 0.75	5.89 ± 0.23	>0.05	5.65 ± 0.65	>0.05	0.09 ± 0.58	–0.15 ± 0.40
TOTAL	(2–36)	22.59 ± 4.00	32.38 ± 1.68	<0.001	29.69 ± 2.97	<0.001	9.79 ± 4.35	7.10 ± 5.17

Data are mean ± SD

months after the final treatment, respectively. “Pain” is the only dimension in which there were no statistically significant changes.

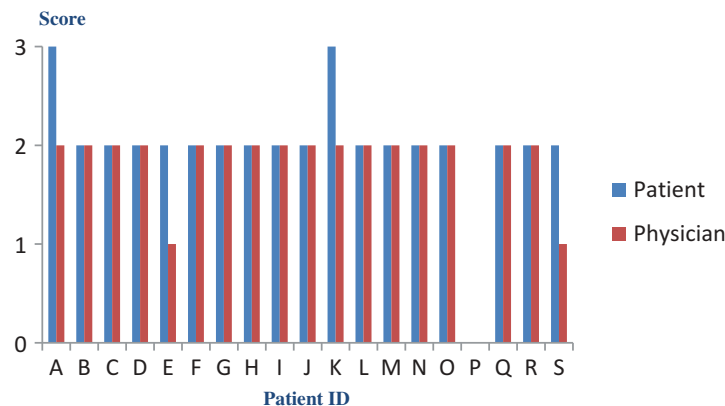
Evaluation of digital images

The average score based on the patients’ responses was 2.00 ± 0.58, with a slightly lower average score of 1.79 ± 0.54 calculated based on the physician’s responses. Both results represent “moderate improvement” according to

the applied scale. The data are shown in Figure 1. Photographs taken at the baseline were compared to those taken 1 month after the final treatment for all 19 study subjects. Samples of the images are available in Figure 2.

Eighteen out of 19 patients (94.7%) reported “moderate” or “excellent” improvement in vulvar appearance. One woman who later decided to quit the study had reported no change.

The physician also identified at least mild improvement on 18 (94.7%) women, with “moderate” or “excellent” improvement on 16 (84.2%) subjects.



0 - No Improvement; 1 - Mild Improvement; 2 - Moderate Improvement; 3 - Excellent Improvement

Figure 1. Improvement in vulvar appearance based on evaluation of digital images.



Figure 2. Examples of digital images taken at the baseline and at the 1-month follow-up visit.

Safety

No adverse events or aggravation were observed.

Discussion

The use of RF for treating facial and body skin laxity has been well described and evidenced in the last decade. However, the application of RF to treat labial skin laxity and improve sexual function is rather new. Therefore, clinical studies of this kind are essential in order to assess the real efficacy of this treatment modality.

All patients in our study reported high levels of satisfaction regarding improvement in the appearance of their genitalia. A significant change in appearance occurred as soon as after the first treatment, with maximum improvement observed after the second treatment. The third and the fourth sessions caused further improvements, but of a lesser magnitude.

With respect to sexual function, all sexually active subjects reported improvement after the treatments. All FSFI dimensions except for "Pain" showed statistical significant score increase, and the changes followed the same patterns as those observed in genital appearance. The best results were seen in better lubrication, ease of reaching orgasm during intercourse, and overall satisfaction with sexual life. No significant improvement in the "Pain" dimension was observed, nor expected. Subjects with increased tightness as a result of the treatments are likely to experience more intensive sensations during sexual intercourse. The overall increase in sexual

function was also significant at the 12-months follow-up, proving the effects to be long lasting.

Our results suggest that one or two treatments may be sufficient to achieve a very reasonable level of improvement in the treated conditions; however, some patients felt that they would benefit from more than four sessions. The FSFI changes exceeded the results achieved by previous studies (5,8), suggesting the investigated device is a highly efficient modality for treating impeded female sexual function.

The results of this clinical study prove that the investigated monopolar RF device provides an effective and safe alternative to existing treatment methods for improving labial laxity and sexual function. Negative side effects of RF treatment are extremely rare.

Declaration of interests

The author is not aware of any affiliations, memberships, funding, or financial holdings that might be perceived as affecting the objectivity of this review.

References

1. Alexiades-Armenakas M. Nonablative skin resurfacing for skin rejuvenation. UpToDate [internet]. Boston: Marcene Alexiander-Armenakas; 2015 Oct [accessed 2016 Nov 20]. <http://www.uptodate.com/contents/nonablative-skin-resurfacing-for-skin-rejuvenation>.
2. Atiyeh BS, Dibo SA. nonsurgical nonablative treatment of aging skin: Radiofrequency technologies between aggressive marketing

- and evidence-based efficacy. *Aesth Plast Surg.* 2009;33;283–94. doi:10.1007/s00266-009-9361-9.
3. Paul M, Blugerman G, Kreindel M, Mulholland RS. Threedimensional radiofrequency tissue tightening: A proposed mechanism and applications for body contouring. *Aesthetic Plast Surg.* 2011;35;87–95. doi:10.1007/s00266-010-9564-0.
 4. Rosen R, Brown C, Heiman J, Leiblum S, Meston C, Shabsigh R, et al. The female sexual function index (FSFI): A multidimensional self-report instrument for the assessment of female sexual function. *J Sex Marital Ther.* 2000;26:191–208. doi:10.1080/009262300278597.
 5. Lordelo P, Leal M, Santos J, Brasil C, Cardoso M, Sartori M. Radiofrequency in the female genital laxity: A pilot study. *Revista Pesquisa Em Fisioterapia.* 2014;4(2):152–59. doi:10.17267/2238-2704rpf.v4i2.448.
 6. Paasch U, Bodendorf MO, Grunewald S, Simon JC. Skin rejuvenation by radiofrequency therapy: Methods, effects and risks. *J Dtsch Dermatol Ges.* 2009;7:196.
 7. Gold M. The increasing use of nonablative radiofrequency in the rejuvenation of the skin. *Expert Rev Dermatol.* 2011;6(2):139–43. doi:10.1586/edm.11.11.
 8. Fistonich I, Turina I, Fistonich N, Marton I. short time efficacy and safety of focused monopolar radiofrequency device for labial laxity improvement—noninvasive labia tissue tightening. Prospective Cohort Study *Lasers Surg Med.* 2016 Mar;48(3):254–59. doi:10.1002/lsm.22450.